

Radiation-Induced Esophagitis on FDG PET Imaging

Peeyush Bhargava, MD,* Phillip Reich, BS,* Abass Alavi, MD,* and Hongming Zhuang, MD, PhD*

Abstract: Whole-body fluorodeoxyglucose positron emission tomographic (FDG PET) imaging is now being used for staging and restaging patients with a variety of cancers. Benign and inflammatory disorders have been reported to take up FDG, and it is important to recognize these on PET images for appropriate interpretation. The authors present a 76-year-old man who was treated with radiation for poorly differentiated nonsmall cell lung cancer and whose posttherapy PET images showed FDG uptake in the region of radiation-induced esophagitis.

Key Words: FDG PET, esophagitis, radiation therapy, inflammation

(*Clin Nucl Med* 2003;28: 849–850)

REFERENCES

1. Fukunaga T, Okazumi S, Koide Y, et al. Evaluation of esophageal cancers using fluorine-18-fluorodeoxyglucose PET. *J Nucl Med.* 1998; 39:1002–1007.
2. Flamen P, Lerut A, Van Cutsem E, et al. Utility of positron emission tomography for the staging of patients with potentially operable esophageal carcinoma. *J Clin Oncol.* 2000;18:3202–3210.
3. Meltzer CC, Luketich JD, Friedman D, et al. Whole-body FDG positron emission tomographic imaging for staging esophageal cancer—comparison with computed tomography. *Clin Nucl Med.* 2000;25:882–887.
4. Lewis PJ, Salama A. Uptake of fluorine-18-fluorodeoxyglucose in sarcoidosis. *J Nucl Med.* 1994;35:1647–1649.
5. Cook GJ, Fogelman I, Maisey MN. Normal physiological and benign pathological variants of 18-fluoro-2-deoxyglucose positron-emission tomography scanning: potential for error in interpretation. *Semin Nucl Med.* 1996;26:308–314.
6. Patel PM, Alibazoglu H, Ali A, et al. Normal thymic uptake of FDG on PET imaging. *Clin Nucl Med.* 1996;21:772–775.
7. Bakheet SMB, Powe J, Ezzat A, et al. F-18-FDG uptake in tuberculosis. *Clin Nucl Med.* 1998;23:739.
8. Bakheet SM, Saleem M, Powe J, et al. F-18 fluorodeoxyglucose chest uptake in lung inflammation and infection. *Clin Nucl Med.* 2000;25:273–278.
9. Zhuang H, Cunnane ME, Ghesani NV, et al. Chest tube insertion as a potential source of false-positive FDG–positron emission tomographic results. *Clin Nucl Med.* 2002;27:285–286.
10. Zhuang H, Alavi A. 18-Fluorodeoxyglucose positron emission tomographic imaging in the detection and monitoring of infection and inflammation. *Semin Nucl Med.* 2002;32:47–59.
11. Beggs AD, Hain SF. F-18FDG–positron emission tomographic scanning and Wegener’s granulomatosis. *Clin Nucl Med.* 2002;27:705–706.
12. Cura M, Smoak W, Dala R. Pulmonary meningioma—false-positive positron emission tomography for malignant pulmonary nodules. *Clin Nucl Med.* 2002;27:701–704.
13. Bakheet SM, Amin T, Alia AG, et al. F-18FDG uptake in benign esophageal disease. *Clin Nucl Med.* 1999;24:995–997.
14. Neto C, Zhuang H, Ghesani N, et al. Detection of Barrett’s esophagus superimposed by esophageal cancer by FDG positron emission tomography. *Clin Nucl Med.* 2001;26:1060.

Received for publication February 24, 2003. Accepted April 14, 2003.
 From the *Division of Nuclear Medicine, Department of Radiology, Hospital of the University of Pennsylvania, Philadelphia, PA.
 Reprints: Hongming Zhuang, MD, PhD, Division of Nuclear Medicine, Hospital of the University of Pennsylvania, 110A Donner Building, 3400 Spruce Street, Philadelphia, PA 19104. E-mail: zhuang@oasis.rad.upenn.edu.
 Copyright © 2003 by Lippincott Williams & Wilkins
 0363-9762/03/2810-0849
 DOI: 10.1097/01.rlu.0000090936.30974.e2

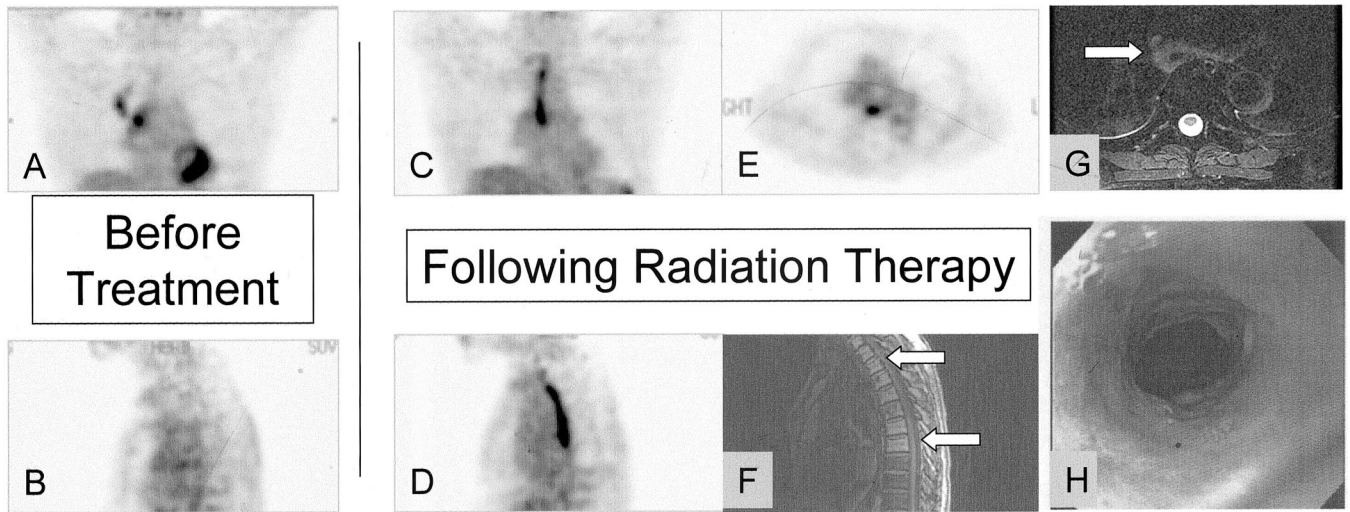


FIGURE 1. The pretherapy positron emission tomographic scan (A, coronal; B, sagittal) shows the primary lung cancer in the right upper lobe and a focus suggestive of nodal metastasis in the right hilum. The follow-up fluorodeoxyglucose (FDG) PET scan after radiation therapy (C, coronal; D, sagittal; E, transaxial) shows complete resolution of the primary lung cancer and nodal metastasis. However, there is a linear focus of intense activity located posteriorly in the thorax and corresponding to the edematous esophagus recognized on the magnetic resonance image (G, arrow). This is consistent with postradiation esophagitis. The patient also had an endoscopic biopsy of the esophagus, which showed necroinflammatory debris in the region with no evidence of malignancy or infection (H). Further evidence linking this focus to the radiation port is provided by the mild reduction in FDG activity seen in the vertebral bodies behind the linear focus in the PET scan (from pretreatment, B; to posttreatment, D) and the presence of fatty marrow on the posttherapy magnetic resonance image (F, arrows). This is consistent with postradiation change. FDG PET has been used successfully in the evaluation of esophageal cancer.¹⁻³ However, increased FDG activity can also be visualized in a variety of nonmalignant chest pathologies.⁴⁻¹² Previous reports have revealed increased FDG activity in nonmalignant esophageal lesions.^{13,14} Our study demonstrated that increased esophageal FDG activity can be caused by previous radiation therapy and therefore should be interpreted with caution in this setting.