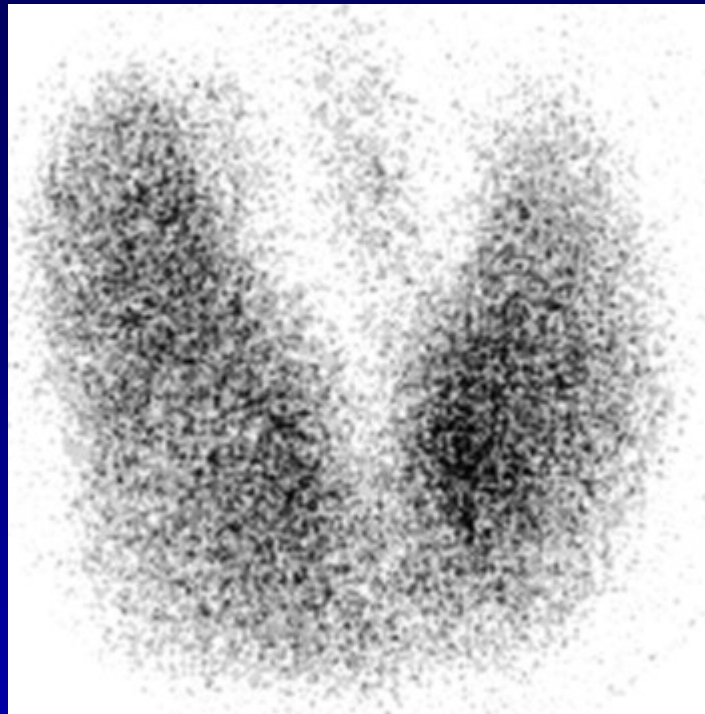



Pinhole images of the neck are acquired in multiple projections, 24hrs after the oral administration of approximately 200  $\mu$ Ci of I123. Usually, 24hr uptake value is also calculated (normal 24 hr uptake is 15-30%) and sometimes 4 or 6 hr uptake value is also calculated, using the thyroid probe.

The image above is from a normal thyroid scan with normal 24 hr uptake value. It shows uniform activity in both lobes and no evidence of any hot or cold nodules. Usually the right lobe of thyroid is larger than the left.

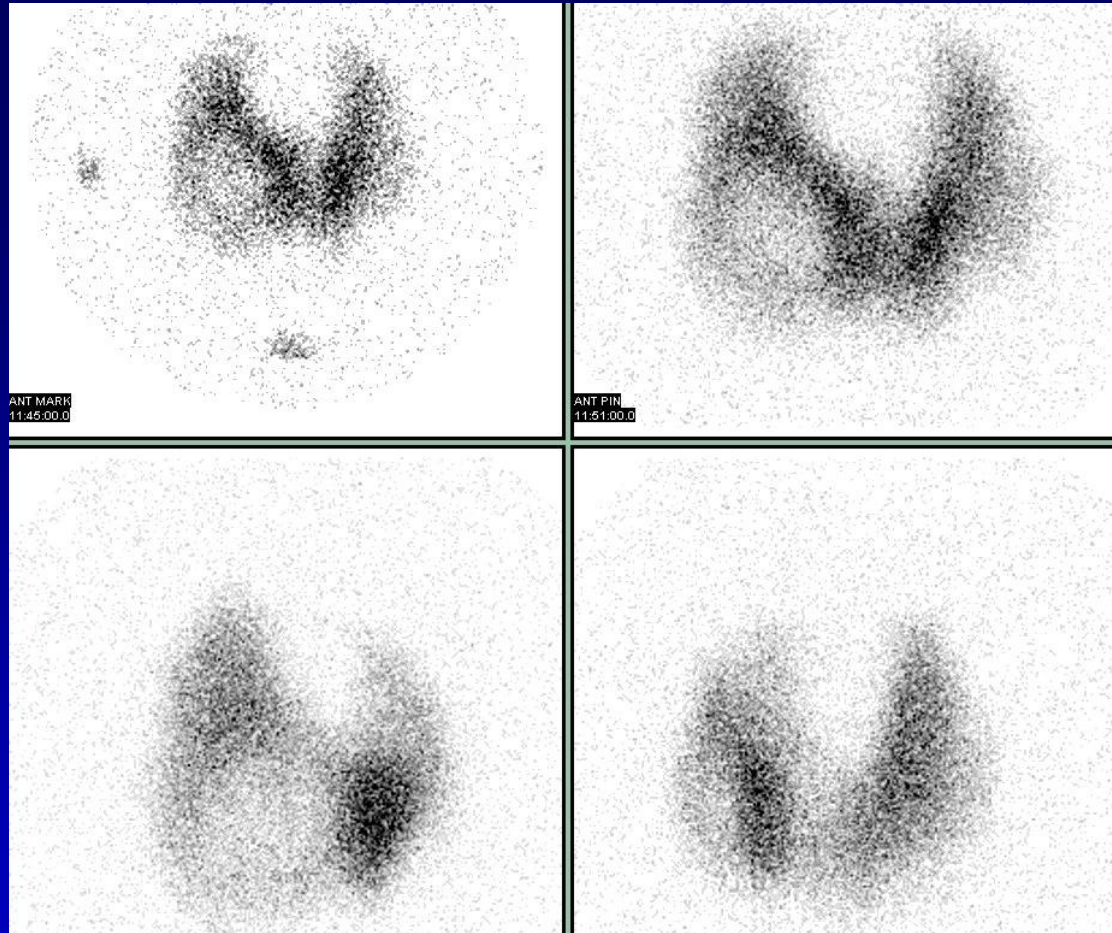


42 yr old male with h/o Graves' disease and prior I<sup>131</sup> treatment presents with hyperthyroidism and undetectable TSH. 2 hr uptake – 20%, 24 hr uptake – 50%.

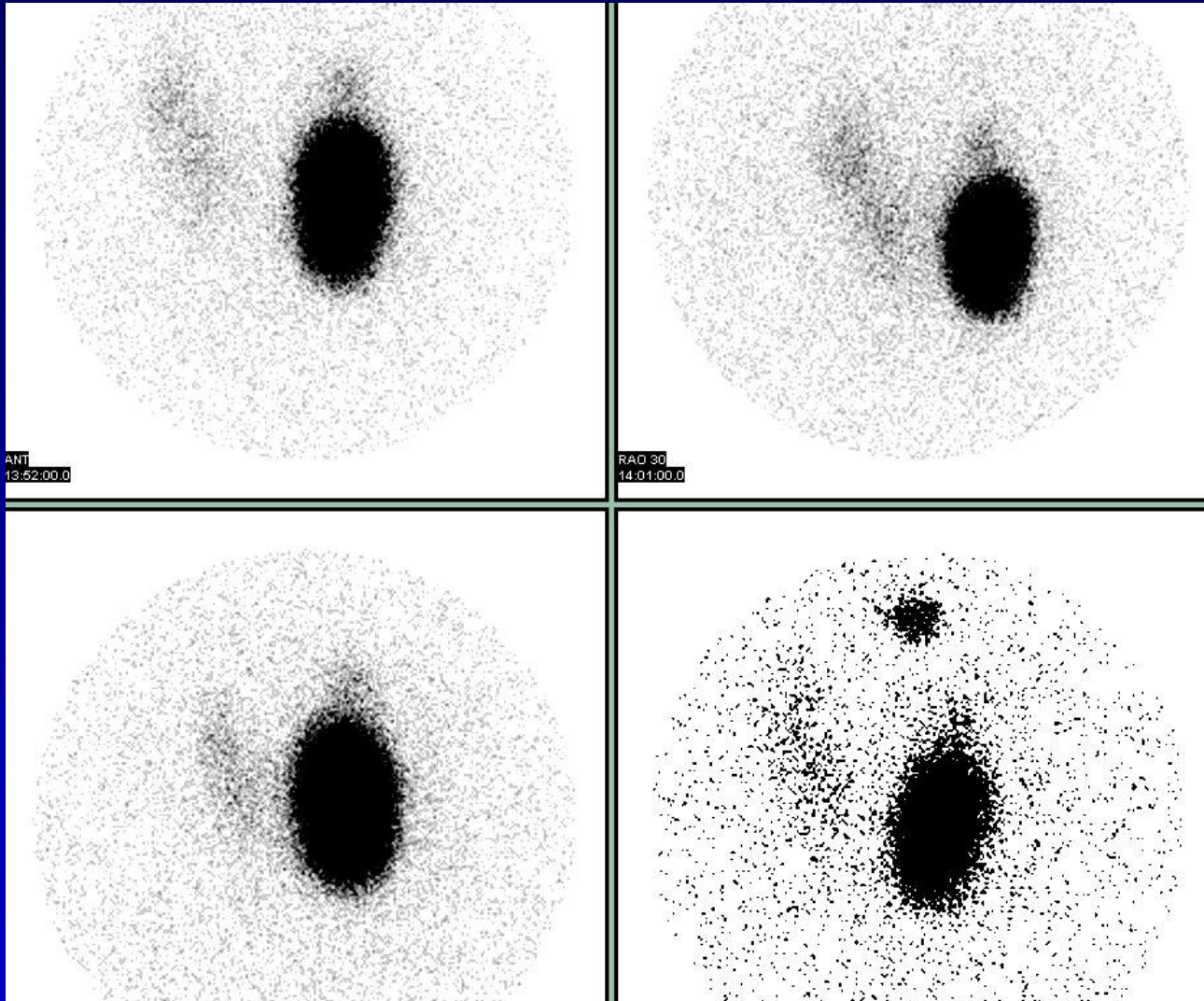
Patient treated with 19 mCi of I<sup>131</sup>. Diffusely enlarged gland, intense I123 uptake, and activity in the pyramidal lobe are the other findings in Grave's disease. Recurrence of Grave's disease, after I131 treatment should be treated with a higher dose of I131. Pyramidal lobe activity is seen as a linear focus arising from the medial aspect of the right or the left lobe of thyroid.



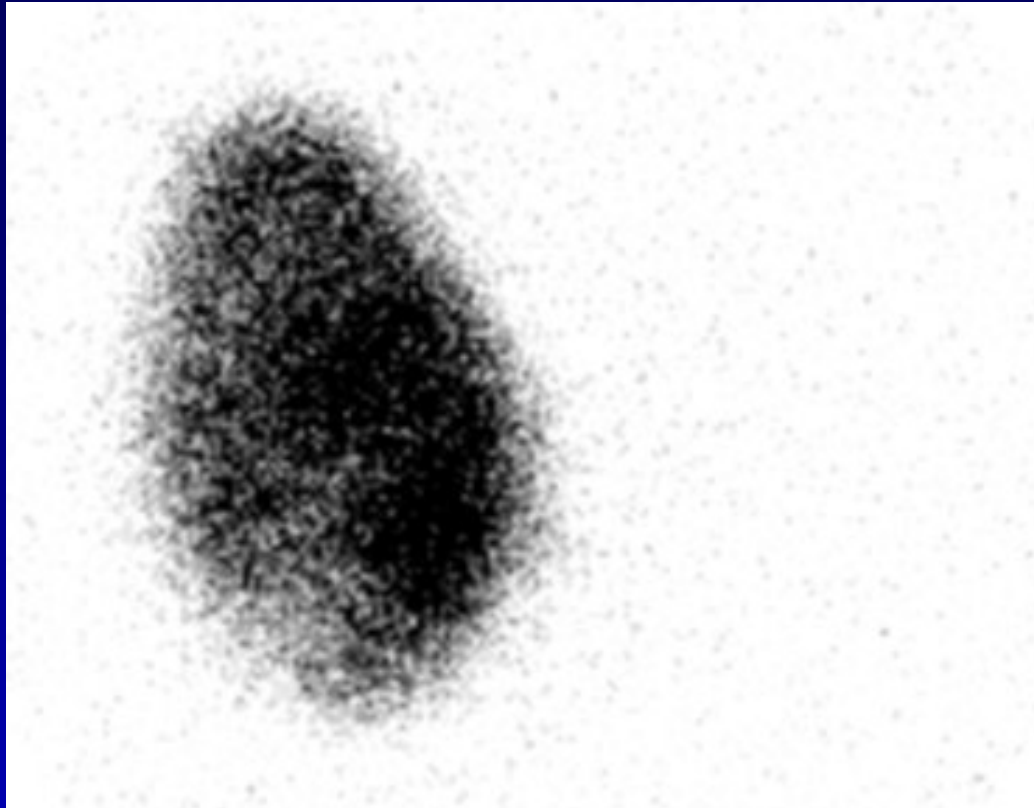
76 yr old female with symptoms of hyperthyroidism, high T4 and undetectable TSH. 2 hr uptake – 3.6%, 24 hr uptake – 2.9%. These findings are likely to be consistent with subacute thyroiditis. There is minimal or no uptake of I123 in the thyroid. This usually resolves over a period of several months, patient becomes euthyroid and the uptake value returns to normal.



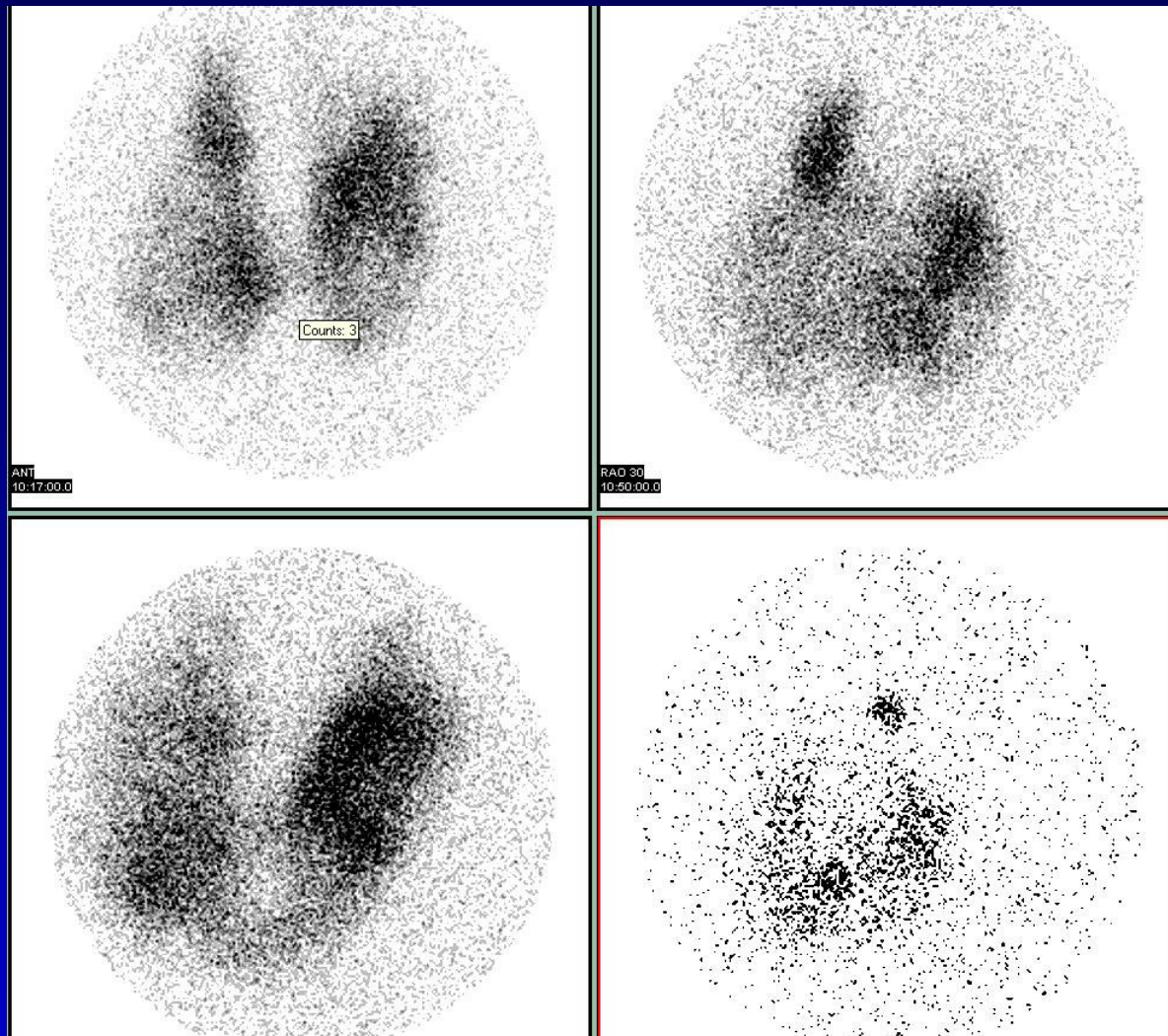
Anterior image with marker, anterior image without marker, RAO view and the LAO view from thyroid scan showing a cold nodule at the inferior pole of the right lobe of thyroid. If this is a solid nodule on the ultrasound, it should be biopsied. The 24 hr uptake was 18%.



The images show a functioning adenoma at the inferior pole of the right lobe of thyroid. The 24 hr uptake value was 46%. There is suppression of uptake in the rest of the thyroid. Findings consistent with solitary toxic nodule.




49 yr old female with h/o thyroid nodule. U/S shows right lobe (2.8×3.4×5.6 cms) heterogenous nodule (2.2×3.2×4.3 cms), no nodules in the left lobe ( 0.7×0.9×3.0 cms) and a complex solid and cystic nodule in the isthmus (0.7×1.1×1.9 cms), to the right of midline. 2 hr uptake – 41% and 24 hr uptake – 62%. The image shows a focus of intense I123 uptake involving almost the whole right lobe of thyroid with suppression of uptake in the left lobe of thyroid. These findings are consistent with solitary toxic nodule, a functioning adenoma. Patient was treated with 20 mCis.



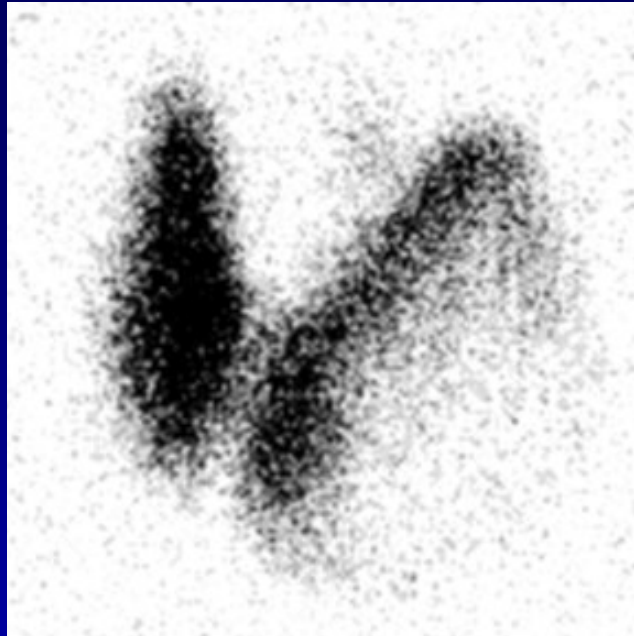
The images above show patchy  $I^{123}$  uptake in both lobes of the thyroid, with scattered areas of increased and decreased activity. The ultrasound shows multiple bilateral nodules. The 24 hr uptake value was within normal limits.

These findings are consistent with multinodular goiter.



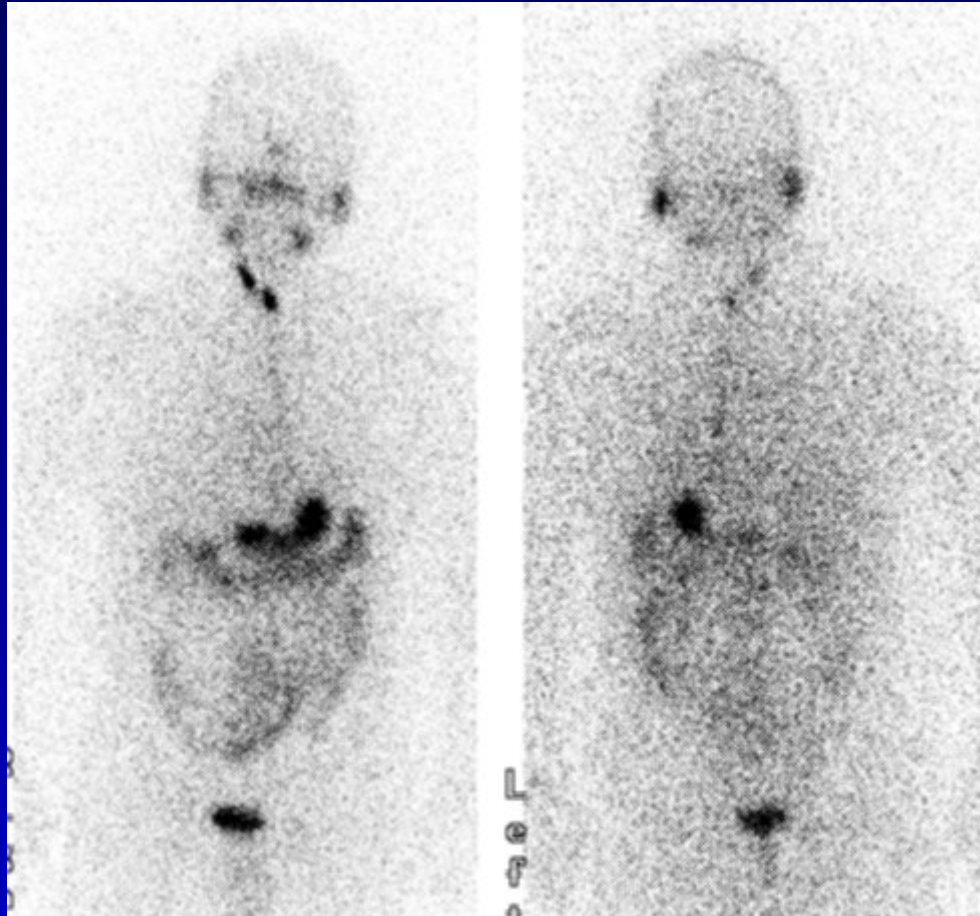
Hyperthyroid 22 year old girl with swelling in the neck and difficulty swallowing. The scan shows foci of increased I123 activity in both lobes of thyroid and an elevated 24 hr uptake value of 46 %. These findings are consistent with toxic multi nodular goiter (Plummer's disease) . The patient was treated with 66 mCi of I131.



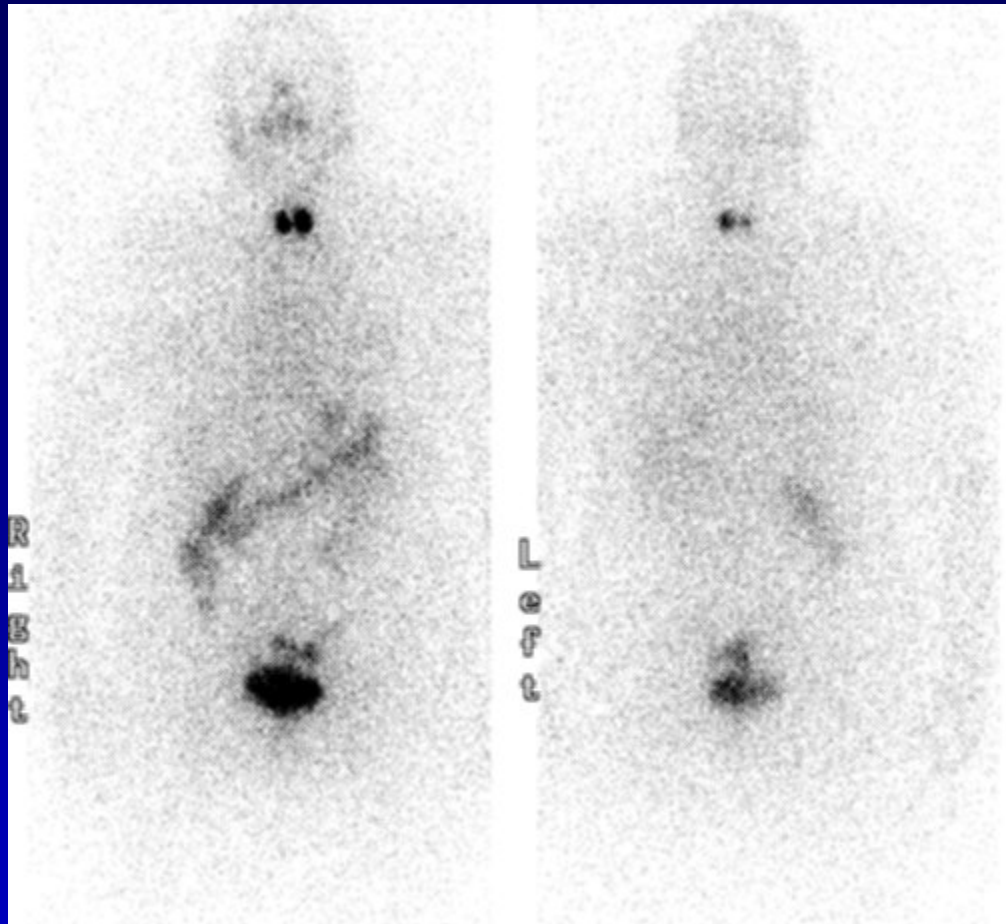


24 yr old euthyroid female with incidentally diagnosed nodule in the left lobe. U/S shows 3 nodules: one in the left mid pole (1.5×2.2×2.0 cms), second in the left lower pole (1.3×1.8×2.0 cms) and a small third nodule in the left side of isthmus. 24 hr uptake – 25%. A large cold nodule is seen in the lateral aspect of the left lobe of thyroid. This being suspicious for malignancy was biopsied.

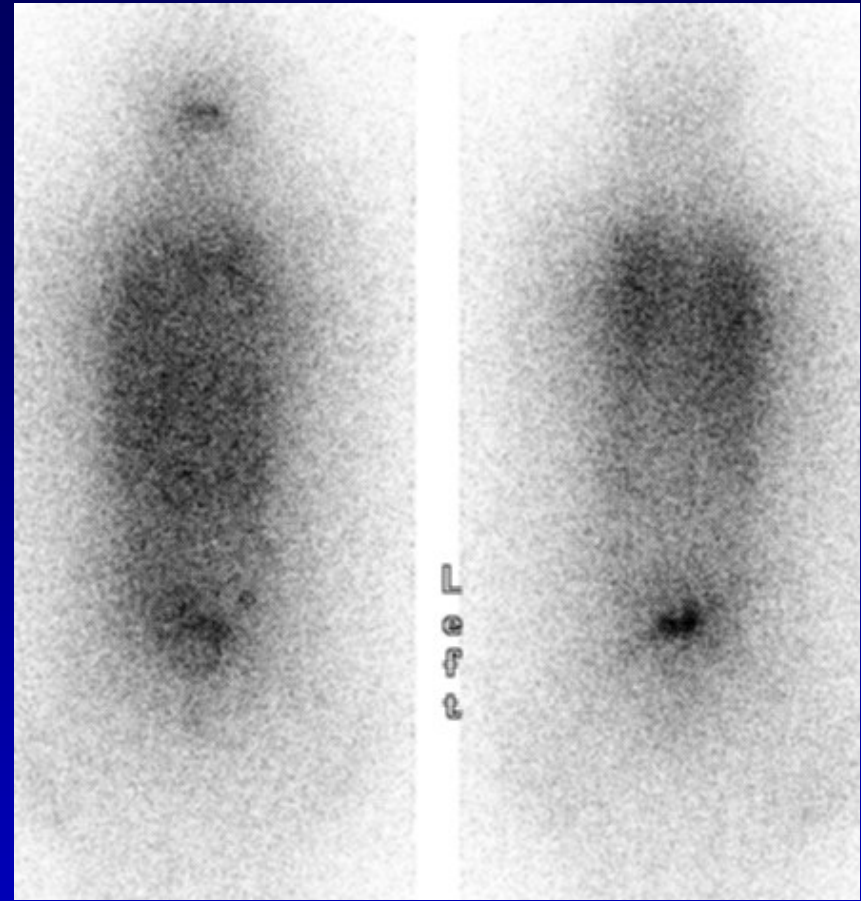
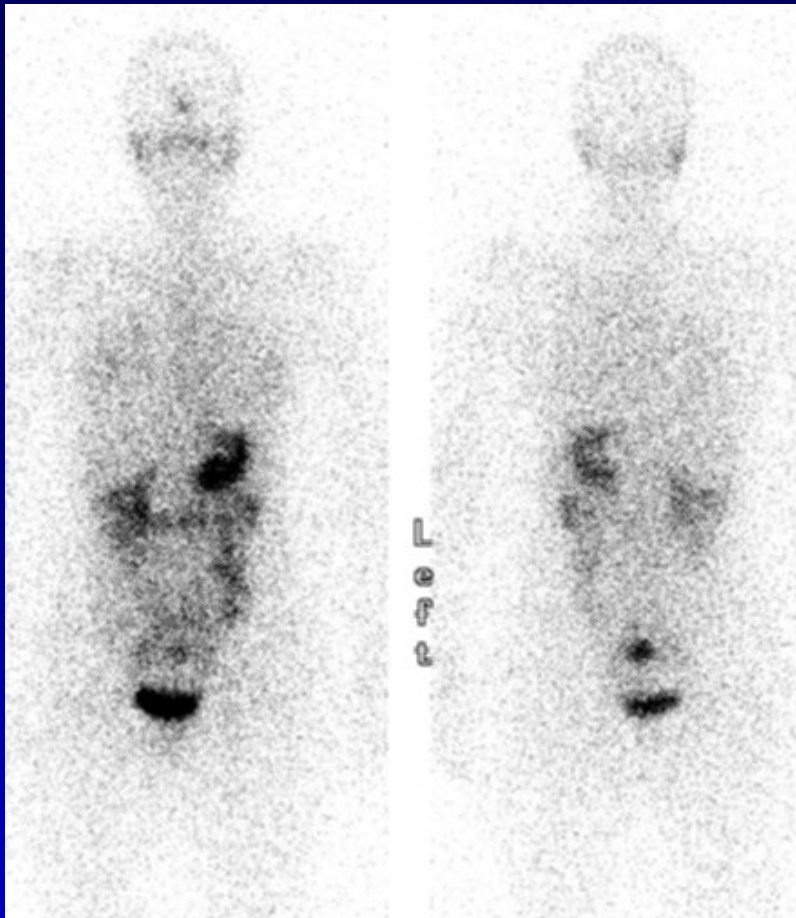
Biopsy revealed papillary thyroid cancer and patient underwent total thyroidectomy. Surgery revealed no involvement of the capsule and no lymphovascular invasion. I<sup>123</sup> whole body scan was performed.



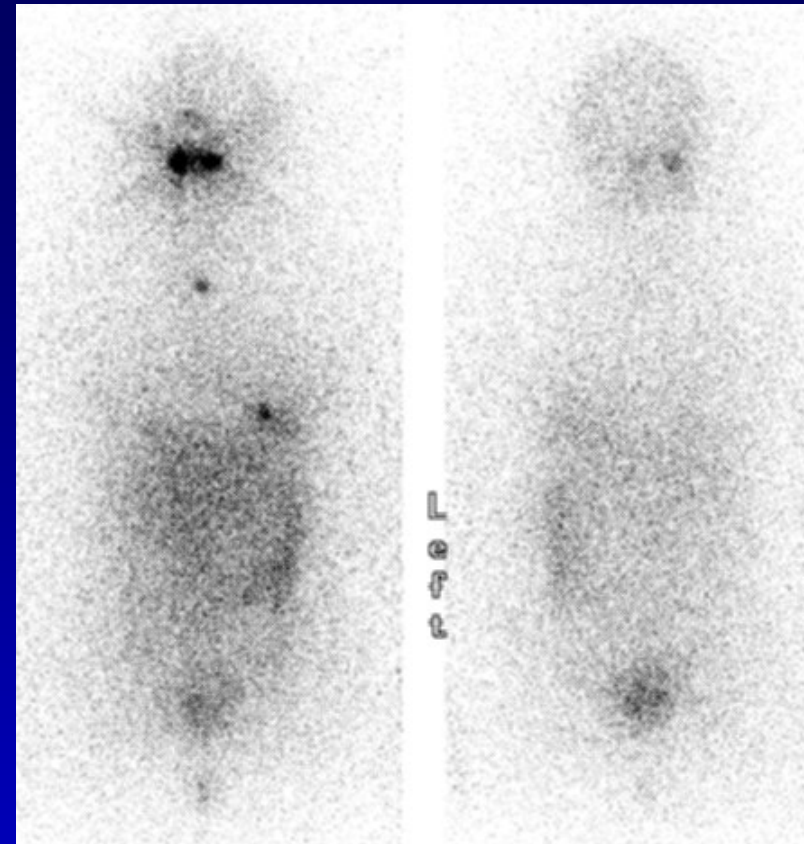
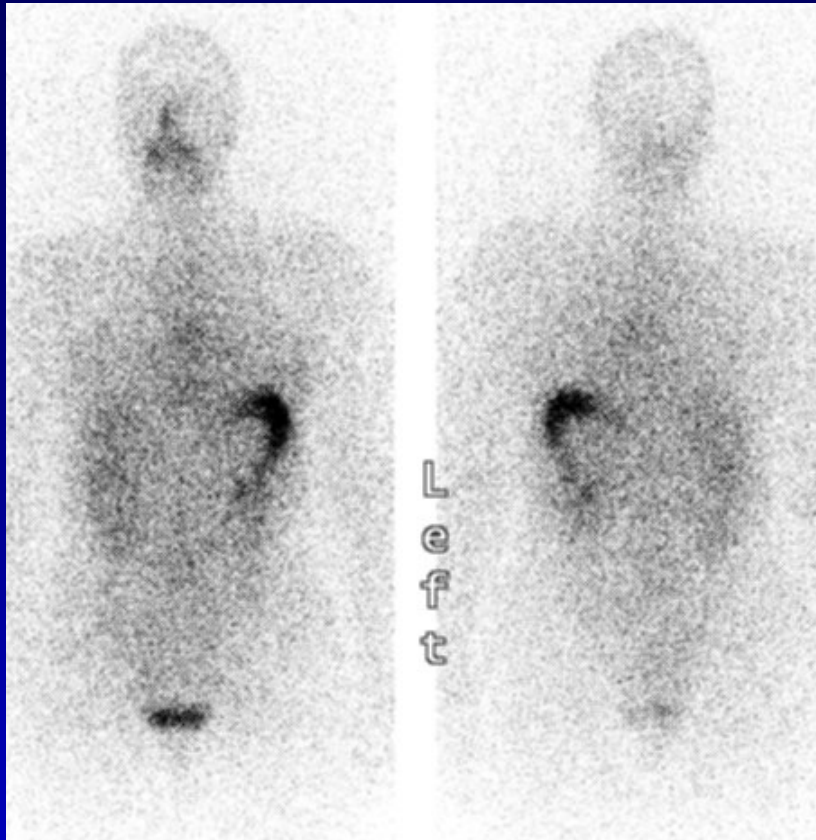
$I^{123}$  whole body scan was acquired in the anterior and posterior projections 24 hrs after the oral administration of 2 mCi of  $I^{123}$ . The scan was performed after T4 withdrawal, TSH was 59. Thyroid remnant was treated with 100 mCi of  $I^{131}$ .  
No definite evidence of metastatic disease was seen.



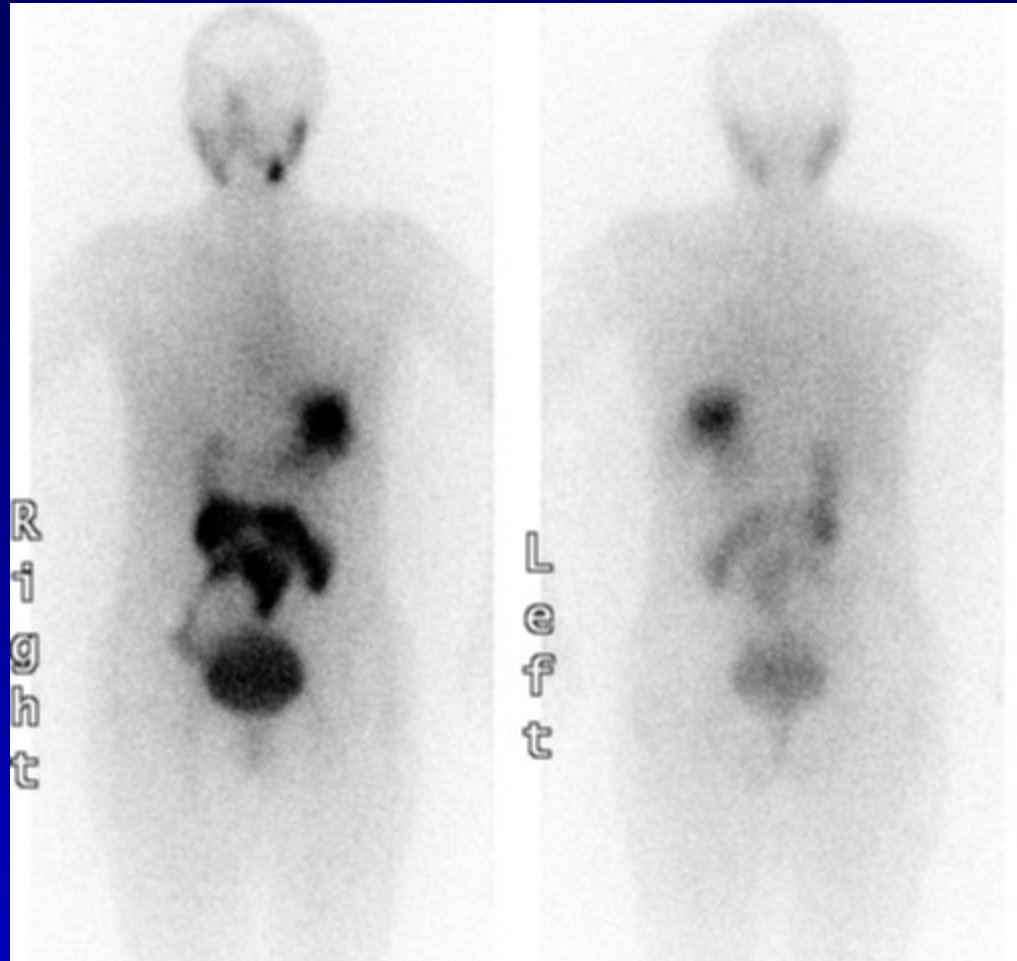
44 yr old female with h/o papillary thyroid cancer, post thyroidectomy (focal capsular invasion, but no lymph vascular involvement) presents with a TSH of 99 for whole body I<sup>123</sup> scan. Thyroid remnant was treated with 100 mCi of I<sup>131</sup> and the post therapy image did not show any new foci of radio-iodine activity.



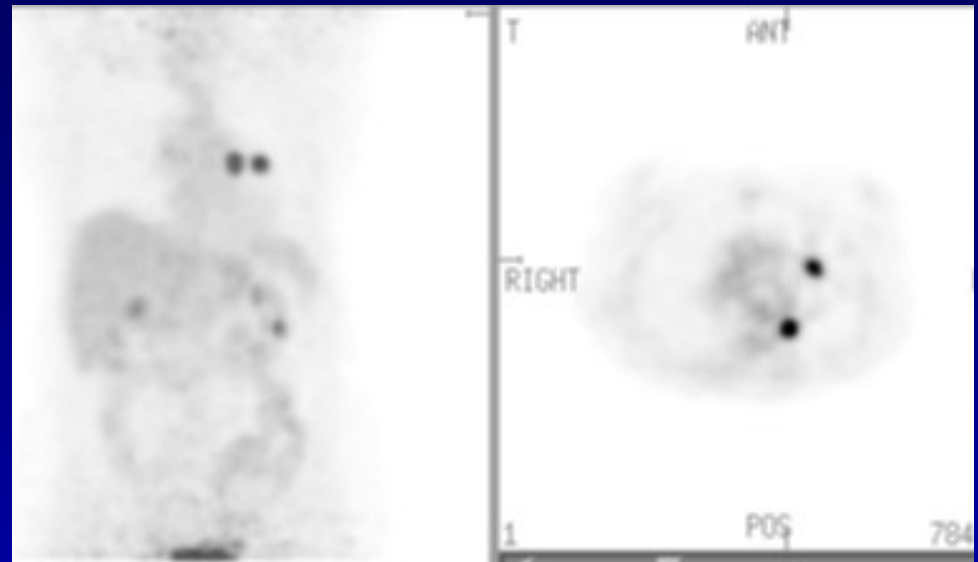
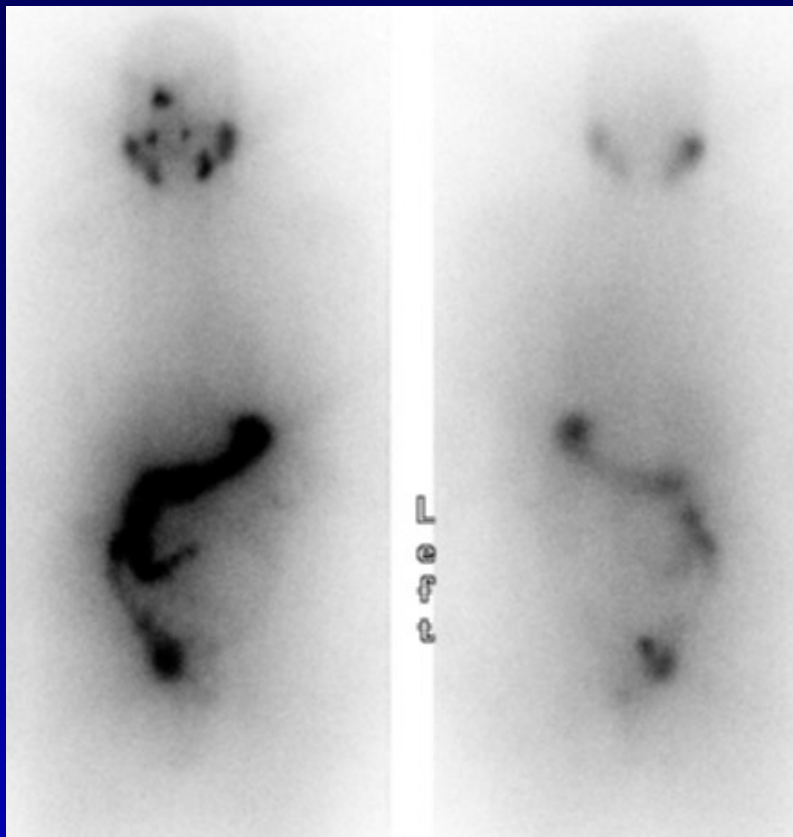
26 yr old female with h/o thyroid cancer, rising thyroglobulin (171), presents with multiple sub centimeter lung nodules on a recent CT scan. She was treated with 175 mCi of I <sup>131</sup> and a 7 day post therapy image was acquired. The whole body scan does not show any definite evidence of metastatic disease and the new lung nodules seen on the CT were presumed to be metastatic and indeed they are visualized on the post therapy scan.



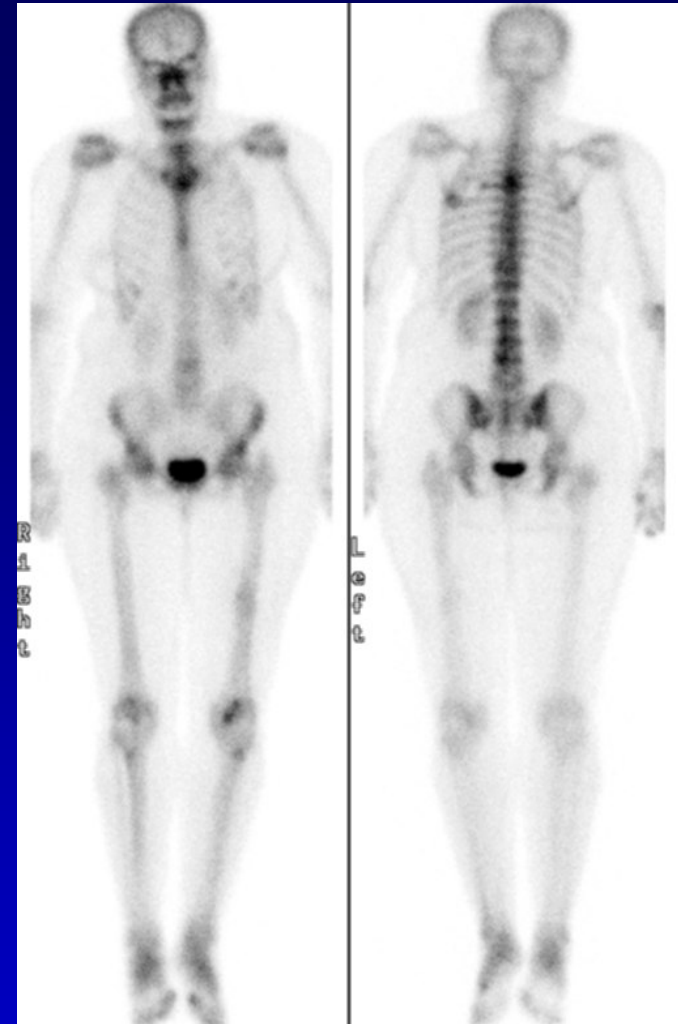
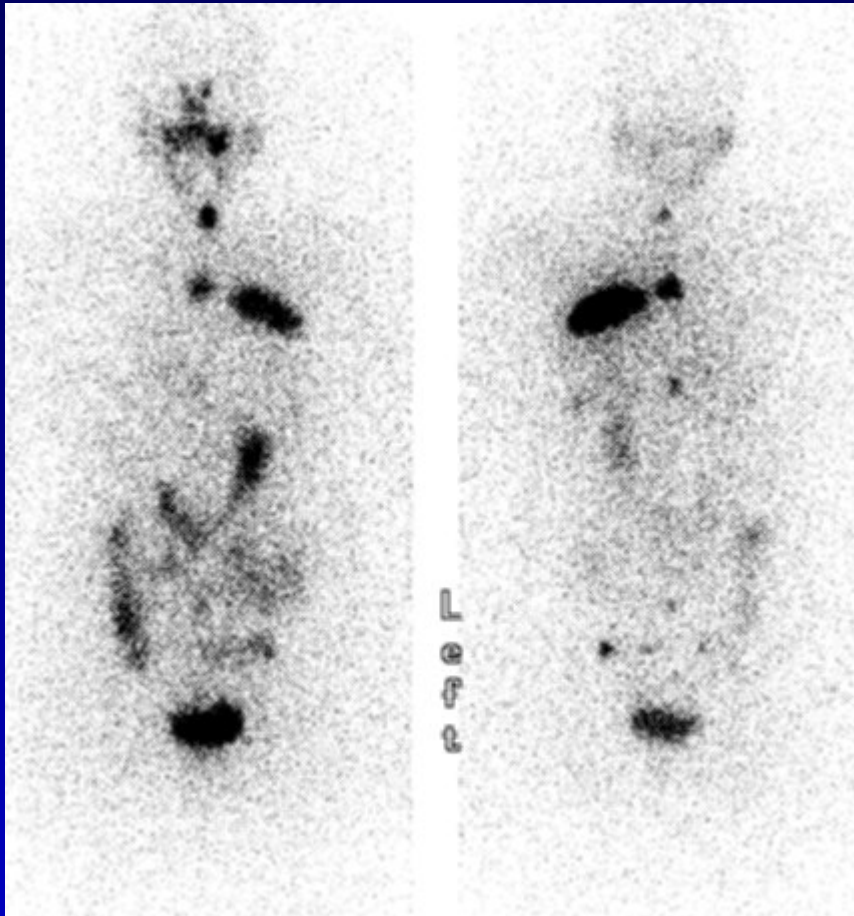
56 yr old female with h/o thyroid cancer, post thyroidectomy, presents with rising thyroglobulin (26, with TSH of 80), - ve ultrasound and multiple lung nodules on a recent CT. Patient was treated with 150 mCi of I 131 and called for a 7 day post therapy image.



24 yr old female with h/o papillary thyroid cancer, post thyroidectomy, neck dissection for cervical lymph node metastasis, presents with sub mandibular lymphadenopathy on the ultrasound (biopsy positive) and a rising thyroglobulin. She was treated with 155 mCi of I 131 and the 7 day post therapy image did not show any new foci.

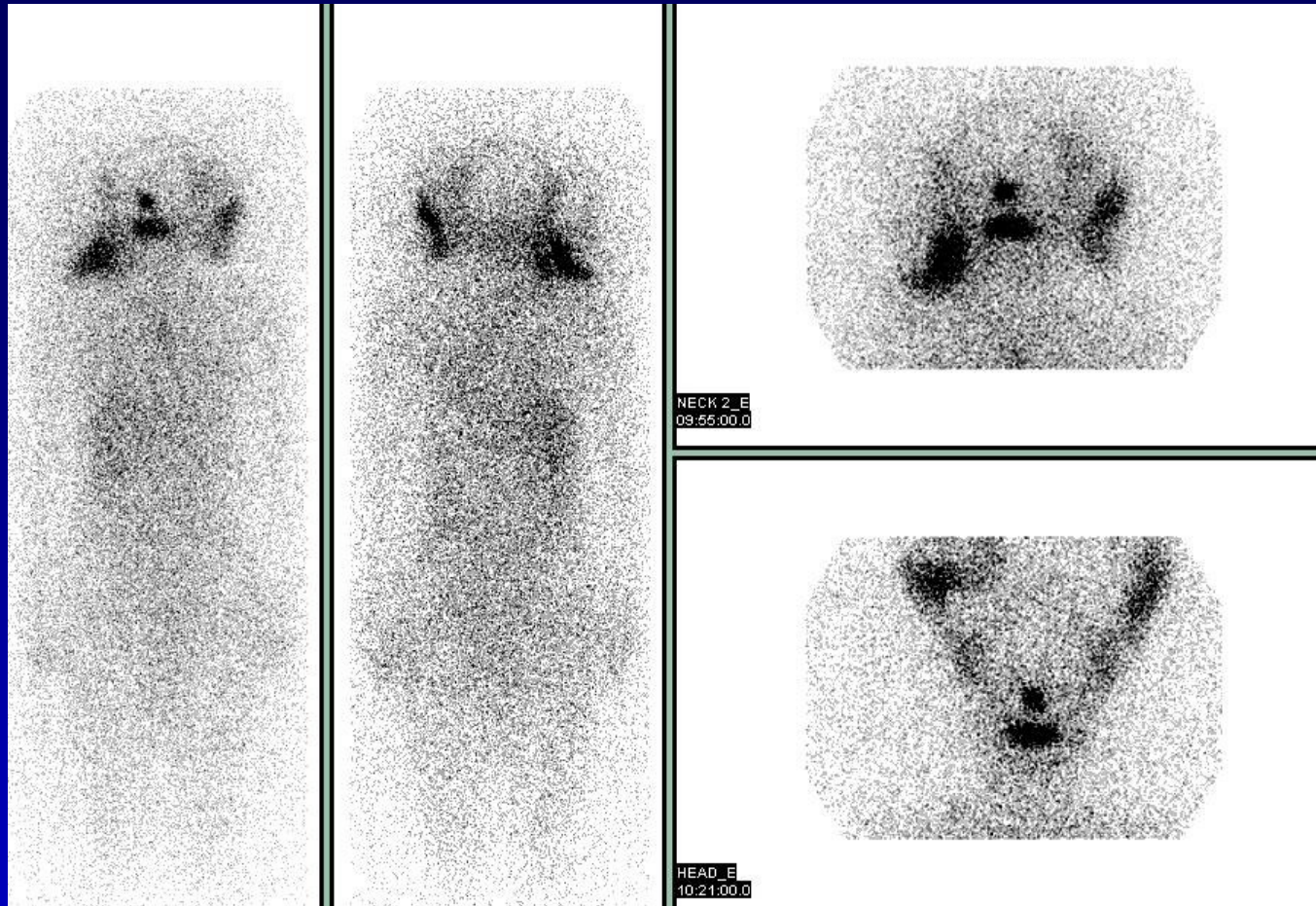


81 yr old male with h/o papillary thyroid cancer and biopsy proven lung metastasis, presents with rising thyroglobulin (102 with TSH of 40). He was treated with 204 mCi of I <sup>131</sup> and the post therapy image also failed to show any abnormality. A PET scan was performed, which shows two malignant left lung nodules, which are not iodine avid. The tumor now is dedifferentiated and takes up FDG. The indication for doing a whole body FDG PET scan in a patient with differentiated thyroid cancer is when the thyroglobulin is rising and the whole body iodine scan or the post therapy scan is negative.

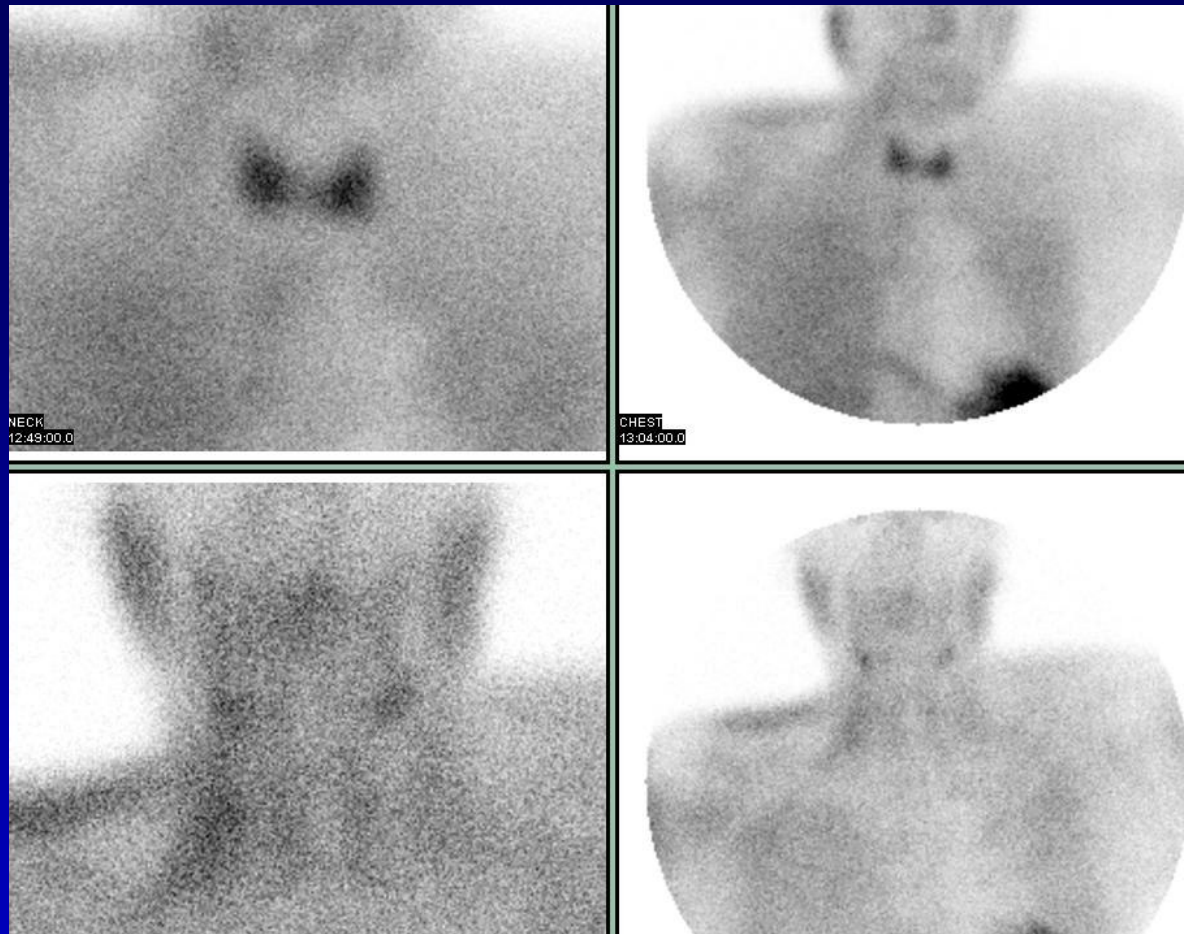


55 yr old female with metastatic thyroid cancer, recent CT shows innumerable lung nodules, lesion in the body T4 vertebra and a destructive left posterior chest wall mass. She was treated with 209 mCi of I <sup>131</sup>. The bone metastasis from thyroid cancer are typically lytic and may not be as clearly visualized on the MDP bone scan as on the I131 whole body scan.

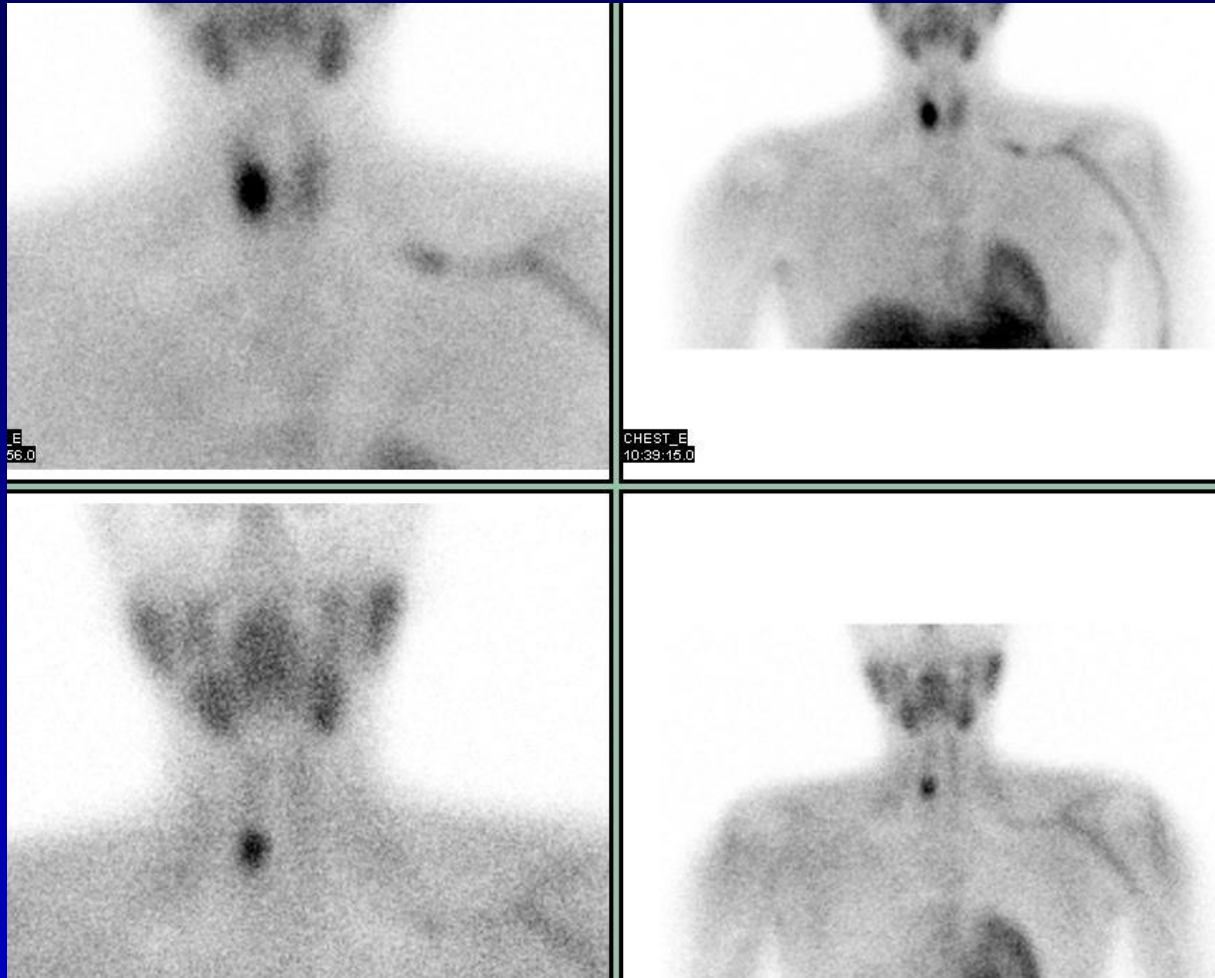




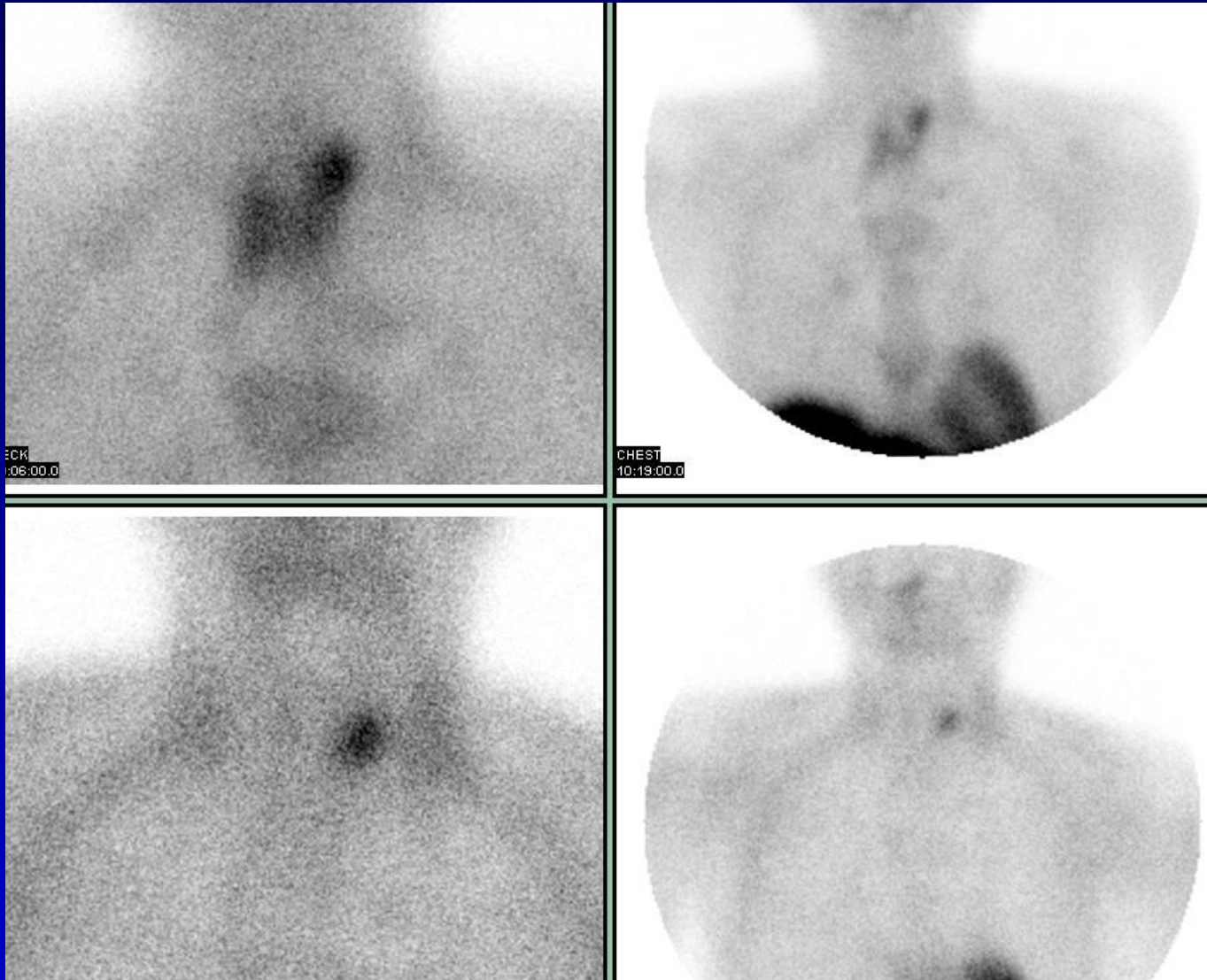
Artifactual I131 activity is seen in the hairs, on the post therapy scan after remnant ablation. This was thought to be from salivary contamination. When the patient was asked to hold her hairs above her head, the activity moved. No activity is seen in the thyroid remnant and no definite evidence of metastasis is seen.



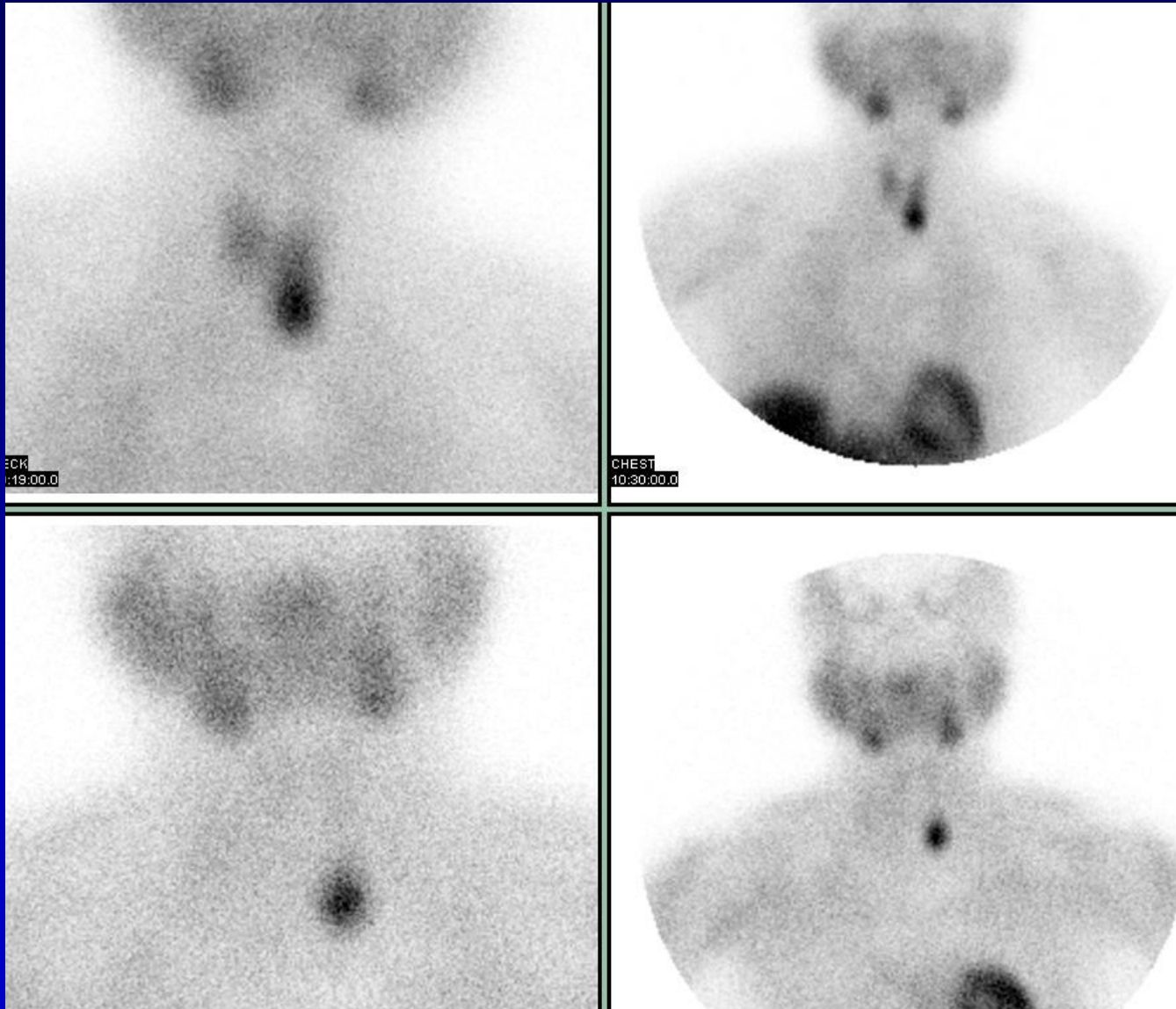
Parathyroid scan: Immediate (10-15min) and delayed (2hr) images of the neck and chest are acquired after intravenous administration of 25 mCi of Tc99mMIBI. Persistent focal activity is suggestive of a parathyroid adenoma. The normal scan above shows normal uptake in the thyroid on the immediate images and good washout of the activity on the delayed images.



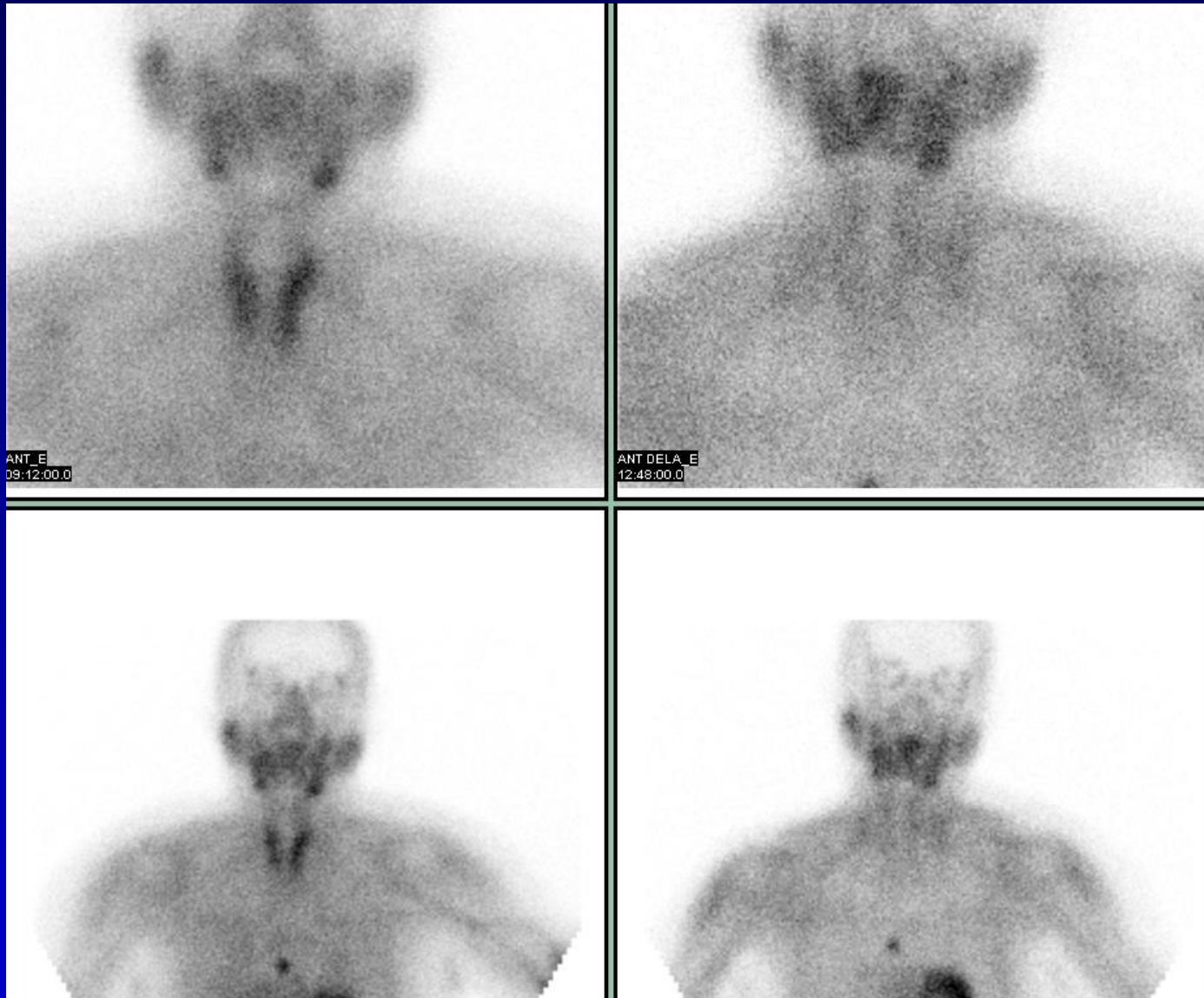
Persistent focal activity at the inferior pole of the right lobe of thyroid, consistent with parathyroid adenoma. Physiologic activity is seen in the walls of the left upper extremity vein, the site of injection.



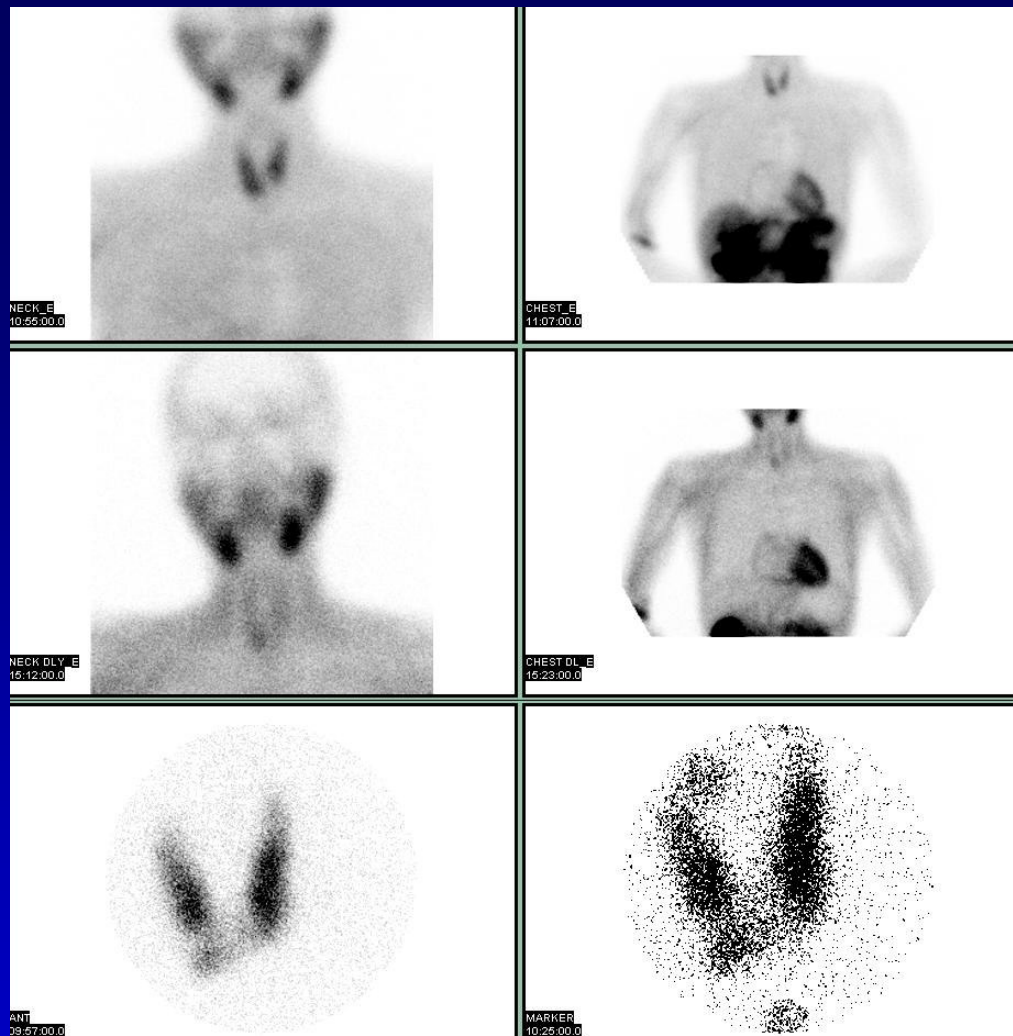
Persistent focal activity at the superior pole of the left lobe of thyroid, consistent with parathyroid adenoma.



Persistent focal activity at the inferior pole of the left lobe of thyroid,  
consistent with parathyroid adenoma.



Persistent focal activity in the mediastinum, consistent with an ectopic parathyroid adenoma. The inferior parathyroid glands are more likely to be ectopic. The thyroid shows normal uptake and washout.



The parathyroid scan shows mild persistent focal activity at the inferior pole of the right lobe of thyroid. The thyroid scan shows I123 activity in this region, consistent with a thyroid adenoma and not a parathyroid adenoma.